
Contrast Enhanced Breast Tomosynthesis: A Promising Tool for Identifying Breast Cancer

Andrew P. Smith, PhD

Overview

Two revolutionary breast-imaging modalities are currently undergoing clinical trials in the United States. Breast tomosynthesis is a method of performing three-dimensional mammography. Contrast enhanced mammography uses contrast agents to target rapid tumor growth. Combining both methods gives us contrast enhanced breast tomosynthesis, which is being evaluated as potentially a powerful new method of identifying breast cancer.

The chances are one in eight that a woman living in the U.S. will get breast cancer in her lifetime. Breast cancer is the third leading cause of death among women in the U.S. and the leading cause of death in women ages 40-55. Screening mammography, through early tumor detection, has reduced this mortality rate by 20% in the last decade. However invaluable mammography has been, its resultant efficacy is lowered by structure noise- tissue overlap that obscures tumors. Mammography is particularly poor in imaging denser breasts, often found in younger women.

It is useful to review the practice of mammography, because it offers clues as to where performance might be improved. In the U. S., women 40 and over are encouraged to go for an annual screening mammogram. During this procedure, two views of each breast are typically taken. If an area is found to be suspicious for pathology, or if an area cannot be clearly seen, the woman has additional views taken of the breast. This series of follow-up images is known as diagnostic mammography and happens perhaps 10% of the time. The vast majority of these women are found to be completely normal.

Of the 10% of all women having a diagnostic mammogram, 20% of the images are still felt to be sufficiently troubling that they are recommended for a tissue biopsy. In this procedure, a thin needle takes a small tissue sample, which is then reviewed by pathologists for the presence of cancer. Of the 20% of women undergoing biopsy, perhaps 25% of these are found to have cancer.

Giving numbers to these percentages, of the U.S. female population of 70 million, about 40 million have yearly screening mammograms and of these, about 4 million have an additional diagnostic workup, 800,000 have biopsies, and of these, 200,000 are identified to have breast cancer. So per

year there are 600,000 biopsies on normal women and about 4 million diagnostic exams on normal women. One goal is to reduce the numbers of these additional tests. Another goal is to improve cancer detection rates, which is frustrated by fundamental limitations of mammography.

Annual Mammography Statistics: U.S. Females

70 million	Women 40 and over eligible for an annual screening mammogram
40 million	Women 40 and over having an annual screening mammogram
4 million	Women having a diagnostic mammogram
800,000	Women have a breast biopsy
200,000	Women identified with breast cancer

Breast Tomosynthesis

Digital mammography, where the detector uses digital technology, has been shown to be superior to conventional analog screen-film mammography, especially in the difficult-to-image denser breasts. However, the long-term promise of digital mammography is probably its use as an enabler of more advanced imaging methods. One of these is known as tomosynthesis. Breast tomosynthesis is a three-dimensional (3-D) digital mammography imaging technology that has shown significant early promise in improving mammography's accuracy.

Breast tomosynthesis consists of taking multiple (usually 11-21) images at multiple angles about a stationary compressed breast, with a total radiation dose similar to conventional mammography. The images are reconstructed into a 3-D image, similarly to CT or MRI images. The value of the 3-D image is tumors are less likely to be hidden amongst normal tissues as they are in a two dimensional (2-D) conventional mammogram. Early clinical trials of tomosynthesis show the potential for both improved cancer detection and the reduction in the need for additional diagnostic imaging for women who are subsequently found to be cancer free.

Contrast Enhanced Mammography

Another imaging modality complementary to breast tomosynthesis, contrast enhanced mammography, involves injecting a contrast agent intravenously while the patient is imaged with a sequence of digital mammograms that show the flow of the contrast agent over time. The contrast agents employed in the study are the same iodine pharmaceuticals commonly used in CT imaging, such as Isovue™ or Omnipaque™.

Contrast enhanced mammography is based on the principle that rapidly growing tumors require an increased supply of blood to support their growth. The contrast agent preferentially accumulates in such areas, and contrast enhanced mammography offers a method of imaging the distribution of the agent in the breast tissue.

The clinical protocol consists of administering the contrast agent through a venous injection in the arm. As the contrast agent distributes throughout the body, a sequence of digital mammograms are taken. The mammograms identify areas with increased contrast agent concentrations.

There are two ways that the images are evaluated. One is to look for the image where the iodine concentration peaks, typically around one minute post injection. Regions having high uptake reflect active tissue growth and may be indicative of malignant tissues. Another method is known as kinetic analysis. In this method, the flow of the iodine into and out of a tissue area is analyzed. Studies have shown that malignant cancers often exhibit a rapid washin and washout of iodine, while benign tissues will have a slow uptake of the iodine over the five-minute study duration.

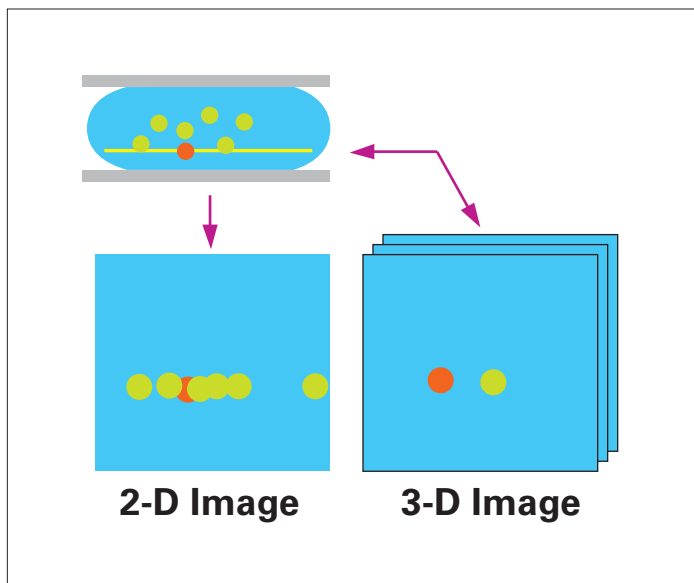


Figure 1.
A cancer, shown in red, is hidden on a 2-D image by overlapping normal tissue (green). It is clearly seen in a single slice from the 3-D breast tomosynthesis image set.

Contrast Enhanced Breast Tomosynthesis

Contrast mammography, as described here, is a 2-D imaging modality. Thus, it suffers from the same limitations as conventional mammography, whereby overlying normal tissues can mask the pathologies of interest. We have seen how tomosynthesis imaging, because it is 3-D, helps improve visibility. It is thus natural to try and combine these two techniques into what is known as contrast enhanced breast tomosynthesis. This means 3-D imaging of the contrast agent. The iodinated contrast agent is administered in the conventional way, and instead of performing 2-D digital mammography, the patient is imaged using the breast tomosynthesis machine. The radiologist will then review the sequence of 3-D images of the drug's flow into and out of the breast tissue.

Contrast enhanced breast tomosynthesis is similar to another imaging modality that is increasingly becoming more commonplace- breast MRI. In breast MRI, the patient is given an injection of an MRI contrast agent, and the patient undergoes a sequence of MRI images. Both methods are looking for local contrast agent concentrations that can be indicative of breast cancer. Both look for washin and washout characteristics to try to differentiate benign from malignant pathologies. And both image the contrast agents using 3-D technology.

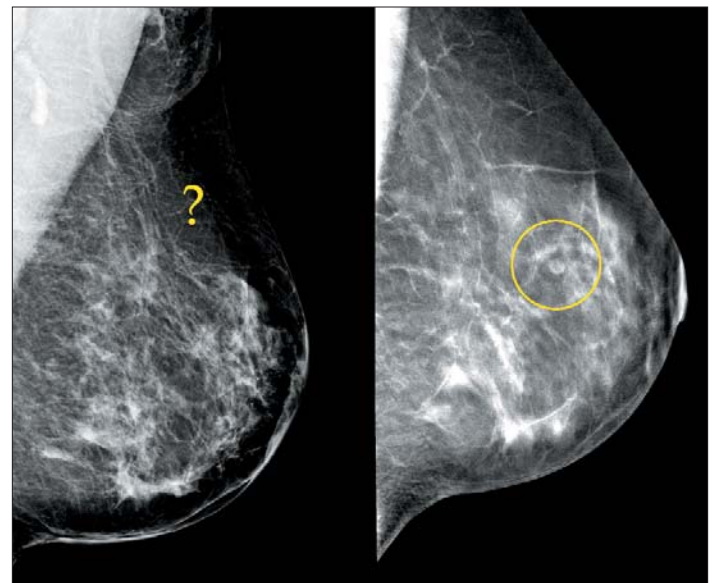


Figure 2.
A benign cyst cannot be seen in the digital mammogram on the left, but is easily identified on the tomosynthesis slice on the right.
Image courtesy Y. Parisky MD, USC Norris Breast Center

Clinical Applications

Contrast tomosynthesis is being investigated for use in a number of clinical areas. One is the differentiation of normal tissue from cancer tissue. Often one cannot make a diagnosis on the basis of tissue appearance, because benign and malignant structures can look identical in an x-ray mammogram. However, it might be expected that a rapidly growing malignant cancer will have increased blood flow and therefore increased contrast agent uptake in its vicinity.

Another use of contrast breast tomosynthesis might be in the identification of secondary cancers following the diagnosis of a primary cancer site. This is helpful in guiding appropriate treatment, such as whether or not a lumpectomy or mastectomy is the appropriate course of action.

Yet another potential area is in monitoring cancer therapy, such as following tumor size during chemotherapy regimens. These are all areas where breast MRI has shown promise. Contrast enhanced breast tomosynthesis might offer similar clinical value, at possibly reduced cost and greater availability than an expensive MRI procedure.

Conclusion

There are many exciting new technologies being applied to the problem of breast cancer detection. All of them are designed to address the accuracy limitations of conventional screen-film mammography. Digital mammography has been proven to be an important new technology, offering numerous advantages in image quality and productivity. But the real advantage of digital is thought to be as an enabling technology. It is spawning huge improvements in computer aided detection (CAD), 3-D tomosynthesis, and contrast-enhanced mammography.

Andrew P. Smith, Ph.D. is Manager of Imaging Science at Hologic, Inc., a women's health imaging company, where he is involved in research and development. He may be contacted at asmith@hologic.com.

Contrast-enhanced breast tomosynthesis is investigational only—no market clearance available.

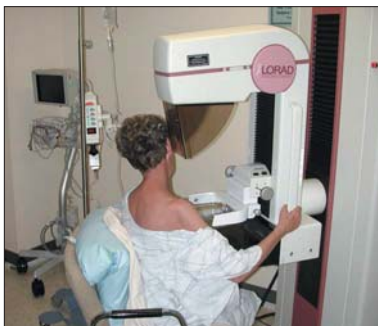

Figure 3. Volunteer being imaged on a prototype contrast enhanced digital mammography platform. Note the power injector for the contrast agent to the left of the patient. Image courtesy USC Norris Breast Center

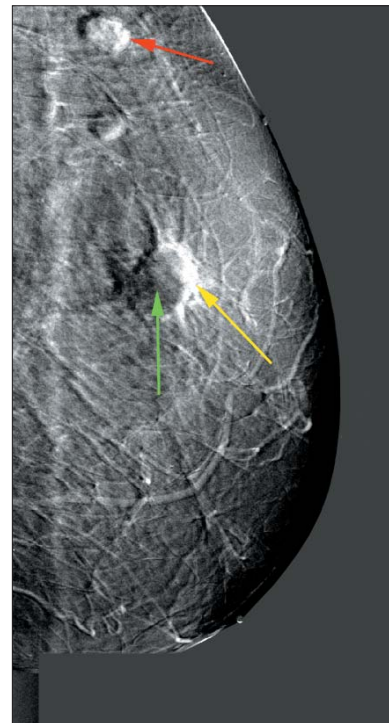


Figure 4. Contrast enhanced digital mammogram shows a cancer with central necrotic core (green arrow), rapidly growing rim enhancement (yellow arrow) and lymph node involvement (red arrow). Image courtesy Y. Parisky MD, USC Norris Breast Center

Hologic, Inc.
35 Crosby Drive
Bedford, MA 01730 U.S.A.
T: 781.999.7300
www.hologic.com
marketing@hologic.com

W-BI-CED May 06
